High-grade prostatic intraepithelial neoplasia is an independent predictor of outcome after radical prostatectomy

Phillip M. Pierorazio, Sarah M. Lambert, Mahesh Matsukhani*, Preston C. Sprenkle, Tara R. McCann, Aaron E. Katz, Carl A. Olsson, Mitchell C. Benson and James M. McKiernan

*Departments of Urology and *Pathology, Columbia University Medical Center, New York, NY, USA*

Accepted for publication 25 May 2007

Study Type – Prognosis (case series)
Level of Evidence 4

OBJECTIVE

To examine the relationship between the presence of high-grade prostatic intraepithelial neoplasia (HGPIN) in retropubic radical prostatectomy (RP) specimens and cancer-specific outcomes, including pathological variables and biochemical disease-free survival (bDFS), as HGPIN shares many histopathological characteristics with prostate carcinoma and has been considered a precursor lesion to prostate cancer.

PATIENTS AND METHODS

The Columbia University Urologic Oncology Database was reviewed; 3460 patients were identified who underwent RP between 1988–2006, and 2133 with or without HGPIN and >12 months of follow-up were included in the analysis. Analysis of variance methods were used to evaluate the relationship between HGPIN and pathological stage, Gleason sum, perineural invasion, multifocality, extraprostatic extension, margin and nodal status. Kaplan-Meier analysis with the log-rank test and a multivariate Cox proportional hazard model fitted for preoperative prostate-specific antigen (PSA) level, Gleason sum and pathological stage were used to assess differences in bDFS.

RESULTS

In all, 1885 (88.4%) patients had HGPIN in the RRP specimen and 248 (11.6%) had no HGPIN. There was no significant difference in the distribution of PSA level ($P = 0.27$), pathological stage ($P = 0.18$) or Gleason sum ($P = 0.84$) between patients with and with no HGPIN. The HGPIN-positive group had higher rates of perineural invasion (69.9 vs 57.5%; $P = 0.003$) and multifocality (63.0 vs 38.4%; $P < 0.001$). Patients with no HGPIN had a better bDFS, at 87.3% vs 81.0% at a median follow-up of 50 months, and 73.6% vs 67.0% at 9 years ($P = 0.045$). The risk of biochemical failure was 1.9 times greater in the HGPIN-positive group than the negative group ($P = 0.006$) when controlling for PSA level, pathological stage and Gleason sum.

CONCLUSIONS

In addition to traditional pathological prognostic variables, the absence of HGPIN in RRP specimens, although found in a minority of patients, denotes a significantly lower rate of tumour multifocality, perineural invasion and ultimately biochemical recurrence.

KEYWORDS

neoplasm, prostatic intraepithelial neoplasia, treatment outcome, pathology, surgical

INTRODUCTION

High-grade prostatic intraepithelial neoplasia (HGPIN) shares many histopathological characteristics with prostate carcinoma and has been considered a precursor lesion to prostate cancer. Recent investigations of HGPIN focused on its ability to predict prostate cancer on repeat biopsies in the modern PSA era. Cancer detection rates on repeat prostate biopsy after a diagnosis of HGPIN vary considerably, with reported rates from 73% to <5%. This discrepancy in the predictive power of HGPIN might also reflect other variables, e.g. the number of biopsy cores sampled and the interval between biopsies [1,2]. Therefore, the prognostic value of HGPIN to predict cancer after a positive biopsy is still under debate.

Irrespective of HGPIN as a possible precursor to prostate cancer, HGPIN is highly associated with the presence of prostate cancer and is present concurrently with adenocarcinoma of the prostate in up to 86.8% of radical prostatectomy (RP) specimens [3]. The presence of high-grade preneoplastic lesions in other cancers, such as intraepithelial neoplasia of the cervix, lobular carcinoma in-situ (CIS) of the breast and CIS of the bladder, has been associated with adverse clinical outcomes and have implications for intervention [4–9]. The present study was designed to examine the relationship between the presence of HGPIN in RP specimens and cancer-specific outcomes, including pathological variables and biochemical disease-free survival (bDFS).

PATIENTS AND METHODS

Using our institutional review board-approved database we identified 3460 patients who had had RP between 1988 and 2006; 2133 with and with no HGPIN were included in the analysis. HGPIN was diagnosed by a review of the pathological reports; slides were not re-reviewed for this analysis. Each sample was evaluated by the case pathologist using a standard protocol

© 2007 THE AUTHORS

FIG. 1. The bDFS between HGPIN and no HGPIN, respectively 87.3% vs 81.0% at a median follow-up of 50 months, and 73.6% vs 67.0% at 108 months (log-rank test, P = 0.045).

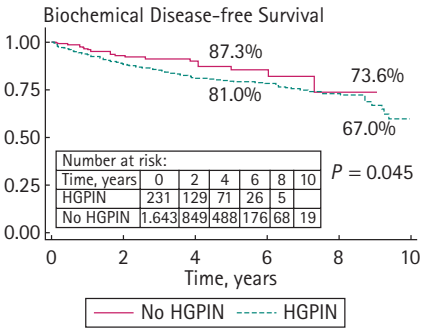

worksheet. The RP specimen was weighed, the right and left surfaces were inked, as were the distal urethral (apical) margin and the bladder neck margin. Sections of the right and left seminal vesicles were taken, followed by a shave of the bladder neck margin, that was bisected into right and left, and embedded margin-side down, as were radial sections of the right and left apical margins. The remaining prostate was sectioned at ≈2 mm intervals, perpendicular to the distal urethra. Starting with the distal section, going proximally, alternate cross-sections were embedded as quadrants (right anterior, left anterior, right posterior and left posterior). The remaining tissue was kept orientated, and if there was no cancer, the remaining tissue was submitted. If there was a question of carcinoma near a margin, or of extraprostatic extension (EPE), then adjacent cross-sections were embedded.

After a microscopic evaluation for Gleason score and permanent mapping of tumour distribution, the presence or absence of PIN and degree of cellular irregularity were reported with the pathological tumour stage. Only cases with definitive mention of the presence or absence of HGPIN on section and analysis of the specimen were included. Cases were excluded (389, 15.4%) if low-grade PIN was found or if the report did not definitively detail the presence or absence of PIN. For EPE, tumour had to be present in adipose tissue, or clearly extrude beyond the greatest outer limit of the adjacent non-neoplastic prostate, with a desmoplastic reaction around it, that clearly did not represent normal prostatic stroma. Multifocality was defined as distinct foci of adenocarcinoma separated by benign prostatic tissue.

As HGPIN was a relatively new diagnosis during the early period of the institutional database, it is possible that the rates of diagnosis and familiarity with the lesion might have varied as time progressed. To assess for any discrepancy in detection rates, the median date of surgery for each group was analysed. In addition, the date of surgery was analysed as a continuous variable in a logistic regression with time zero set as the date of RP for the first patient to be entered in the database.

The relationship between HGPIN and various pathological and clinical variables were evaluated using ANOVA techniques. Pathological variables included pathological stage, Gleason sum, perineural invasion (PNI), multifocality, EPE, margin status and nodal status. Clinical variables included PSA level, pathological stage and Gleason score.

In the survival analysis, to be considered free of disease patients were required to have an undetectable PSA level after RP of <0.2 ng/mL. Kaplan-Meier analysis with the log-rank test was used to assess differences in bDFS between the groups. A univariate Cox proportional hazard model was created to evaluate HGPIN as a predictor of outcome. A multivariate Cox proportional hazard model was then fitted to predict bDFS using preoperative PSA level, Gleason sum, pathological stage and HGPIN.

RESULTS

In all, 1885 (88.4%) patients had HGPIN in the RP specimen; HGPIN was not identified in sections submitted for 248 (11.6%) cases. The median age was 60.7 years: 60.3 years in the group with no HGPIN and 60.7 years in the group with HGPIN. The median date of surgery was comparable between the groups: July 1999 for patients with no HGPIN and December 1999 for those with HGPIN. When fitted into a logistic regression the date of surgery was a not a significant predictor of the presence of HGPIN ($P = 0.91$), indicating that there was no discrepancy in the rates of diagnosis over time.

There was no difference in the distribution of PSA levels ($P = 0.27$, based on a logarithmic distribution of PSA), pathological stage ($P = 0.18$) or Gleason sum ($P = 0.84$) between the groups. The HGPIN-positive patients had higher rates of PNI (69.9% vs 57.5%; $P = 0.003$) and multifocality (63.0% vs 38.4%; $P < 0.001$). Differences were not significant in the comparison of EPE, nodal or margin status (Table 1).

Patients with no HGPIN had a greater bDFS, with a predicted DFS of 73.6% vs 67.0% at 9 years ($P = 0.045$; Fig. 1). At 50 months, the median follow-up, the bDFS was 87.3% for the HGPIN-negative group and 81.0% for the HGPIN-positive group.

In the multivariate Cox hazard model, preoperative PSA level, Gleason sum and pathological stage (all $P < 0.001$) were validated as predictors of failure. In addition, HGPIN was an independent predictor of bDFS, with a hazard ratio (95% CI) of 1.87 (1.18–2.96; $P = 0.007$). A second multivariate analysis was used to determine the prognostic influence of HGPIN, using initial preoperative characteristics (PSA level, Gleason sum, pathological stage) while also controlling for PNI and multifocality. Multifocality and PNI were not significant predictors of outcome ($P = 0.39$ and 0.77, respectively) while HGPIN remained a significant predictor of outcome (hazard ratio 1.76, 1.04–2.97, $P = 0.03$).

DISCUSSION

PIN is characterized by pre-existing prostatic ducts lined by atypical, presumably neoplastic, cells. In 1986, McNeal and Bostwick [10] completed a histopathological evaluation, classifying PIN into mild, moderate and severe dysplasia. Bostwick *et al.* [11] described PIN as having the cellular qualities of cancerous cells (including increased cellular size, greater variability of size, irregular cell spacing and nuclear and nucleolar atypia) while remaining distinct from adenocarcinoma by maintaining an intact glandular basal cell architecture. Those authors documented a correlation between the presence of HGPIN and prostate cancer; specimens with multiple foci of HGPIN had a higher likelihood of concomitant prostate cancer. Therefore, that study concluded that HGPIN was a premalignant lesion and a precursor to invasive adenocarcinoma. The authors also noted that both HGPIN and prostatic adenocarcinoma are more frequently located in the peripheral zone of the prostate. Despite this conclusion, it has been difficult to prove definitely that dysplastic foci of HGPIN have transformed into invasive carcinoma.

© 2007 THE AUTHORS
JOURNAL COMPILATION © 2007 BJU INTERNATIONAL

Since 1986, the relationship between HGPIN and prostate cancer described by McNeal and Bostwick has been supported by other investigators, with rates of concurrent HGPIN and prostate cancer of 82–100% of pathology specimens [3,12]. As a result, a patient with HGPIN in a prostate biopsy specimen in the absence of prostate cancer is monitored more frequently than a patient with a prostate biopsy showing BPH or other benign pathology. The yield of prostate cancer detection on repeat TRUS-guided prostate biopsy in patients with HGPIN is 4.5–79%; recent studies from 2004 to 2005 show 20.8–30.5% of patients with prostate cancer on repeat biopsy [2,13–15]. This discrepancy has led to continued controversy about the role of HGPIN in the natural history of prostate cancer. Therefore, despite continued research during the previous two decades, the specific association between PIN and prostate cancer has yet to be determined.

There was well-documented premalignant intraepithelial lesions for several solid-organ tumours, including urothelial, breast, cervical, uterine, endometrial, gastrointestinal and respiratory carcinomas. Brawer [16] described a multistep theory of the development of neoplasia into malignant carcinoma; PIN and many of these other tissue equivalents meet the criteria of preneoplastic lesions outlined in Brawer's theory. In cancers of other tissue types, the presence of HGPIN or CIS often portends a worse prognosis. Studies evaluating the impact of CIS in bladder cancer showed repeatedly that the presence of CIS with concurrent superficial lesions confers a higher risk of recurrence and progression than superficial papillary lesions in the absence of CIS, and as a result requires more aggressive treatment [4,8,9]. The presence of lobular CIS in the pathology specimen in patients with early-stage breast cancer is associated with a higher recurrence rate after breast-conserving surgery [5]. Similarly, features of high-grade cervical intraepithelial neoplasia were shown to predict microinvasion of concurrent adenocarcinoma [7]. Therefore, in the present study we evaluated HGPIN as a potential harbinger of worse disease in patients with prostate cancer and sought to determine the relationship between HGPIN and pathological and cancer-specific outcomes.

The hypothesis that the HGPIN portends a worse prognosis is based on the previously documented correlation between HGPIN on prostate biopsy and the risk of prostate cancer on future biopsy. The contrary hypothesis, that HGPIN might be a potentially beneficial pathological finding, was also considered, as the presence of HGPIN might indicate that the carcinoma is less aggressive, thereby allowing the premalignant lesion to remain for longer. Qian *et al.* [17] found a positive correlation between total volume of HGPIN with volume of cancer, pathological stage and tumour grade. These findings support the theory of this analysis, that HGPIN is an indicator of a worse clinical outcome as it correlates with worse cellular characteristics of concomitant prostatic adenocarcinoma. The direct biological link between HGPIN and worse features of adenocarcinoma has yet to be clearly elucidated. However, it might be hypothesized that the biology of HGPIN is such that: (i) it describes a field defect in the entire gland, leading to more diffuse disease; (ii) it allows for potentially greater de-

TABLE 1
The pathological characteristics of the study population

Variable	n (%) HGPIN Yes	No	Total	P
No. of patients	1885 (88.4)	248 (11.6)	2133	
Serum PSA, ng/mL				0.26*
0–4	275 (16.8)	40 (17.1)	355 (16.3)	
>4–10	1109 (67.8)	150 (64.1)	1415 (64.8)	
>10	252 (15.4)	44 (18.8)	413 (18.9)	
Total	1636	234	2183	
Pathological stage				0.18
p0	10 (0.5)	2 (0.8)	12 (0.6)	
p1	0	0	0	
p2	1338 (71.1)	186 (75.3)	1524 (71.6)	
p3	502 (26.7)	52 (21.1)	554 (26.0)	
p4	33 (1.8)	7 (2.8)	40 (1.9)	
Total	1883	247	2130	
Gleason score				0.84
<7	676 (36.1)	99 (40.4)	775 (36.6)	
=7	972 (51.9)	104 (42.5)	1076 (50.8)	
>7	224 (12.0)	42 (17.1)	266 (12.6)	
Total	1872	245	2117	
PNI				0.003
Yes	1065 (69.9)	115 (57.5)	1180 (68.4)	
No	459 (30.1)	85 (42.5)	544 (31.6)	
Total	1524	200	1724	
Vascular invasion				0.36
Yes	190 (13.5)	24 (12.5)	214 (13.3)	
No	1222 (86.5)	168 (87.5)	1390 (86.7)	
Total	1412	192	1604	
Multifocal				<0.001
Yes	944 (63.0)	76 (38.4)	1020 (60.1)	
No	554 (37.0)	122 (61.6)	676 (39.9)	
Total	1498	198	1696	
Positive nodes				0.49
Yes	22 (1.3)	3 (1.3)	41 (1.3)	
No	1660 (98.7)	227 (98.7)	1887 (98.7)	
Total	1682	230	1928	
EPE				0.57
Yes	1177 (73.8)	164 (75.6)	1543 (73.6)	
No	419 (26.3)	53 (73.8)	555 (26.5)	
Total	1596	217	2098	
Margin status				0.12
Positive	453 (24.5)	51 (20.8)	504 (24.1)	
Negative	1394 (75.5)	194 (79.2)	1588 (75.9)	
Total	1847	245	2092	

**Calculation of the distribution of serum PSA level was based on the logarithmic distribution of PSA.*

© 2007 THE AUTHORS
JOURNAL COMPILATION © 2007 BJU INTERNATIONAL

differentiation of adenocarcinoma cells before diagnosis; or (iii) that the cellular characteristics of HGPIN define cell lines destined to be worse cancers than those cancers that arise 'de novo.' Although further basic science and pathological studies will be necessary to determine the relationship, the present study indicates that HGPIN might indicate worse cellular characteristics of adenocarcinoma, as shown by the greater rates of multifocality and PNI.

HGPIN has been found concurrently with prostate cancer at a high rate, i.e. 82% of patients with prostate cancer had concurrent HGPIN in the original series by McNeal and Bostwick [10], as did 87% in a similar study [3], and 100% [12] in a smaller series of 61 prostates. The present series had a similar rate of patients with and with no HGPIN (88% vs 12%, respectively). Nevertheless, the large number of patients in the present series provides a relatively large number of controls (248 with no HGPIN) than in previous studies. When the groups were analysed by PSA level, pathological stage and Gleason sum (established as the best predictors of outcome after RP [18]) the population of patients with HGPIN had similar prostate cancer characteristics to those with no HGPIN. By further controlling for these characteristics in a multivariate analysis, it was clear that HGPIN was a predictor of worse pathological features (PNI and multifocality) and biochemical recurrence. To ensure that the worse pathological features were not confounding the survival data, these features (PNI and multifocality) were added to the multivariate model, with no resulting changes, strengthening the relationship between HGPIN and biochemical failure.

Despite the strength of there being many patients in the present study, there are limitations to the analysis of PIN. First, critics will argue that this study necessitated a pathologist-confirmed review of the slides. However, the many specimens evaluated by surgical pathologists using worksheets and similar criteria for HGPIN diagnosis reflects the practice patterns in the larger urological community, and is therefore considered a strength of this analysis. Also, as this study evaluated clinical (and not cellular or pathological) variables, and clinical decision-making is not often based on a review of slides, we feel that this analysis better represents the experience of practising physicians. An additional issue was that the diagnosis of HGPIN by pathologists has become increasingly more common over the past two decades. This trend has the potential to affect the analysis, as patients from the earlier years might have a lower likelihood of being diagnosed with HGPIN than would patients evaluated more recently. Pathologists at our institution have used a consistent and strict definition in the diagnosis of HGPIN over the past two decades. Also, the use of a reporting template requires each pathologist to address the presence or absence of HGPIN. To evaluate this potential discrepancy, the median year of surgery was compared and found to be comparable between the groups. In a more robust analysis, the date of surgery was evaluated as a continuous variable and determined to have an insignificant role in predicting HGPIN. We therefore conclude that trends in the histological diagnosis of HGPIN had a minimal or equal effect upon both groups and do not affect the present analysis.

The application of HGPIN as a predictor of worse pathological and clinical outcome might enhance the accuracy of the current models used to predict bDFS. However, the clinical use of this association is limited, secondary to the overwhelming presence of HGPIN in RP specimens, with >80% of RP specimens containing HGPIN and the small, but significant, survival advantage determined in those patients with no HGPIN. Therefore, the stronger implication might be that the lack of HGPIN is beneficial at the time of RP and those patients lacking HGPIN have a better likelihood of local cancer control. The notion of improved local cancer control offers many directions for future study, including a means to detect this small percentage (10–20%) of patients with prostate cancer who lack HGPIN. However, in the short term, it emphasizes the importance of identifying and documenting HGPIN in all RP specimens.

An additional important implication of this study is that the presence of HGPIN in the RP specimen might be recognized as a marker of more aggressive local prostate cancer, specifically PNI and multifocality. Because HGPIN is found at such a high rate concomitantly with prostate cancer, it is a valid suggestion that patients with HGPIN on screening prostate biopsy require careful consideration when being selected and counselled about RP. The outcome of a patient diagnosed with prostate cancer after several benign biopsies with no HGPIN might be very different from a patient with several HGPIN biopsies before the discovery of carcinoma. With more research and careful analysis of HGPIN as a biological and epidemiological phenomenon, the role of bilateral nerve-sparing surgery could be re-considered in patients who have high-volume, concurrent HGPIN and prostate carcinoma on biopsy. Those patients with HPGIN might have a higher risk of locally advanced disease and in certain circumstances it might warrant more aggressive surgical dissection during removal of the prostate. It would be premature to suggest changes in clinical practice, yet the unspecified role of HGPIN in prostate cancer development, prognosis and treatment will continue to be better understood as our studies and investigations continue.

In conclusion, we documented the association between HGPIN and prostate cancer, but the nature of this association has yet to be fully elucidated. The present study showed a greater likelihood of multifocality and PNI in patients with prostate cancer and concurrent HGPIN, and patients lacking HGPIN at the time of RP had a better bDFS.

CONFLICT OF INTEREST

None declared. Source of funding: Doris Duke Charitable Foundation.

REFERENCES

1 **Haggman MJ, Adolfsson J, Khoury S, Montie JE, Norlen J.** Clinical management of premalignant lesions of the prostate. WHO Collaborative Project and Consensus Conference on Public Health and Clinical Significance of Premalignant Alterations in the Genitourinary Tract. *Scand J Urol Nephrol Suppl* 2000; **205**: 44–9

2 **Moore CK, Karikehalli S, Nazeer T, Fisher HA, Kaufman RP Jr, Mian BM.** Prognostic significance of high grade prostatic intraepithelial neoplasia and atypical small acinar proliferation in the contemporary era. *J Urol* 2005; **173**: 70–2

3 **Kovi J, Mostofi FK, Heshmat MY, Enterline JP.** Large acinar atypical hyperplasia and carcinoma of the prostate. *Cancer* 1988; **61**: 555–61

4 **Utz DC, Farrow GM.** Management of carcinoma in situ of the bladder: the case for surgical management. *Urol Clin North Am* 1980; **7**: 533–41

© 2007 THE AUTHORS
JOURNAL COMPILATION © 2007 BJU INTERNATIONAL

5 **Horst KC, Smitt MC, Goffinet DR, Carlson RW.** Predictors of local recurrence after breast-conservation therapy. *Clin Breast Cancer* 2005; **5**: 425–38

6 **Wright TC Jr, Cox JT, Massad LS, Carlson J, Twiggs LB, Wilkinson EJ; American Society for Colposcopy and Cervical Pathology.** 2001 consensus guidelines for the management of women with cervical intraepithelial neoplasia. *Obstet Gynecol* 2003;189: 295–304

7 **Arends MJ, Buckley CH, Wells M.** Aetiology, pathogenesis, and pathology of cervical neoplasia. *J Clin Pathol* 1998; **51**: 96–103

8 **Heney NM, Ahmed S, Flanagan MJ *et al.*** Superficial bladder cancer: progression and recurrence. *J Urol* 1983; **130**: 1083–6

9 **Wolf H, Olsen PR, Hojgaard K.** Urothelial dysplasia concomitant with bladder tumours: a determinant for future new occurrences in patients treated by full-course radiotherapy. *Lancet* 1985; **1**: 1005–8

10 **McNeal JE, Bostwick DG.** Intraductal dysplasia. a premalignant lesion of the prostate. *Hum Pathol* 1986; **17**: 64–71

11 **Bostwick DG, Brawer MK.** Prostatic intra-epithelial neoplasia and early invasion in prostate cancer. *Cancer* 1987; **59**: 788–94

12 **Tronosco P, Grignon DJ, Babian RJ, Von Eschenbach AC, Ro JY, Ayala AG.** Prostatic intraepithelial neoplasia and invasive prostatic adenocarcinoma in cystoprostatectomy specimens. *Urology* 1989; **34** (Suppl): 52–6

13 **Schlesinger C, Bostwick DG, Iczkowski KA.** High-grade prostatic intraepithelial neoplasia and atypical small acinar proliferation: predictive value for cancer in current practice. *Am J Surg Pathol* 2005; **29**: 1201–7

14 **Gokden N, Roehl KA, Catalona WJ, Humphrey PA.** High-grade prostatic intraepithelial neoplasia in needle biopsy as risk factor for detection of adenocarcinoma: current level of risk in screening population. *Urology* 2005; **65**: 538–42

15 **Naya Y, Ayala AG, Tamboli P, Babaian RJ.** Can the number of cores with high-grade prostate intraepithelial neoplasia predict cancer in men who undergo repeat biopsy? *Urology* 2004; **63**: 503–8

16 **Brawer MK.** Prostatic intraepithelial neoplasia: a premalignant lesion. *Hum Pathol* 1992; **23**: 242–8

17 **Qian J, Wollan P, Bostwick DG.** The extent and multicentricity of high-grade prostatic intraepithelial neoplasia in clinically localized prostatic adenocarcinoma. *Hum Pathol* 1997; **28**: 143–8

18 **Kattan MW, Wheeler TM, Scardino PT.** Postoperative nomogram for disease recurrence after radical prostatectomy for prostate cancer. *J Clin Oncol* 1999; **17**: 1499–507

Correspondence: James M. McKiernan, Department of Urology, Herbert Irving Pavilion – 11th Floor, 161 Fort Washington Ave., New York, NY 10032, USA.
e-mail: jmm23@columbia.edu

Abbreviations: **(HG)PIN**, (high-grade) prostatic intraepithelial neoplasia; **RP**, radical prostatectomy; **CIS**, carcinoma in situ; **bDFS**, biochemical disease-free survival; **EPE**, extraprostatic extension; **PNI**, perineural invasion.

© 2007 THE AUTHORS
JOURNAL COMPILATION © 2007 BJU INTERNATIONAL